



magnetic
M A L L E T

HORIZONTAL BONE EXPANSION

Surgical procedure

A. In edentulous ridge expansion technique, a palatal incision in crestal direction is performed, and partial-thickness buccal and lingual flaps are raised, followed when necessary by two vertical incisions defining the surgical area. Fig.1



Fig 1. Schematic view of partial thickness flap and crestal incision with a blade inserted on Magnetic Mallet

B. After the flaps are reflected, two transperiosteal incisions are made into the bone parallel to the incisions; two vertical grooves are formed by the penetration of the vestibular cortical plate of the bone at 1 mm away from the teeth. In the absence of teeth, the discharges are performed 3-5 mm away from the closest implant planned site. The crestal incision is continued into the bone to perform an intraosseous groove with a blade. FIG 2

Bone incision is performed by blade directly attached and pushed by Magnetic mallet.

Mallet is set to apply **different forces** of different strength, depending on bone density.

The blade penetrates down to 7-11 mm into the alveolar ridge.

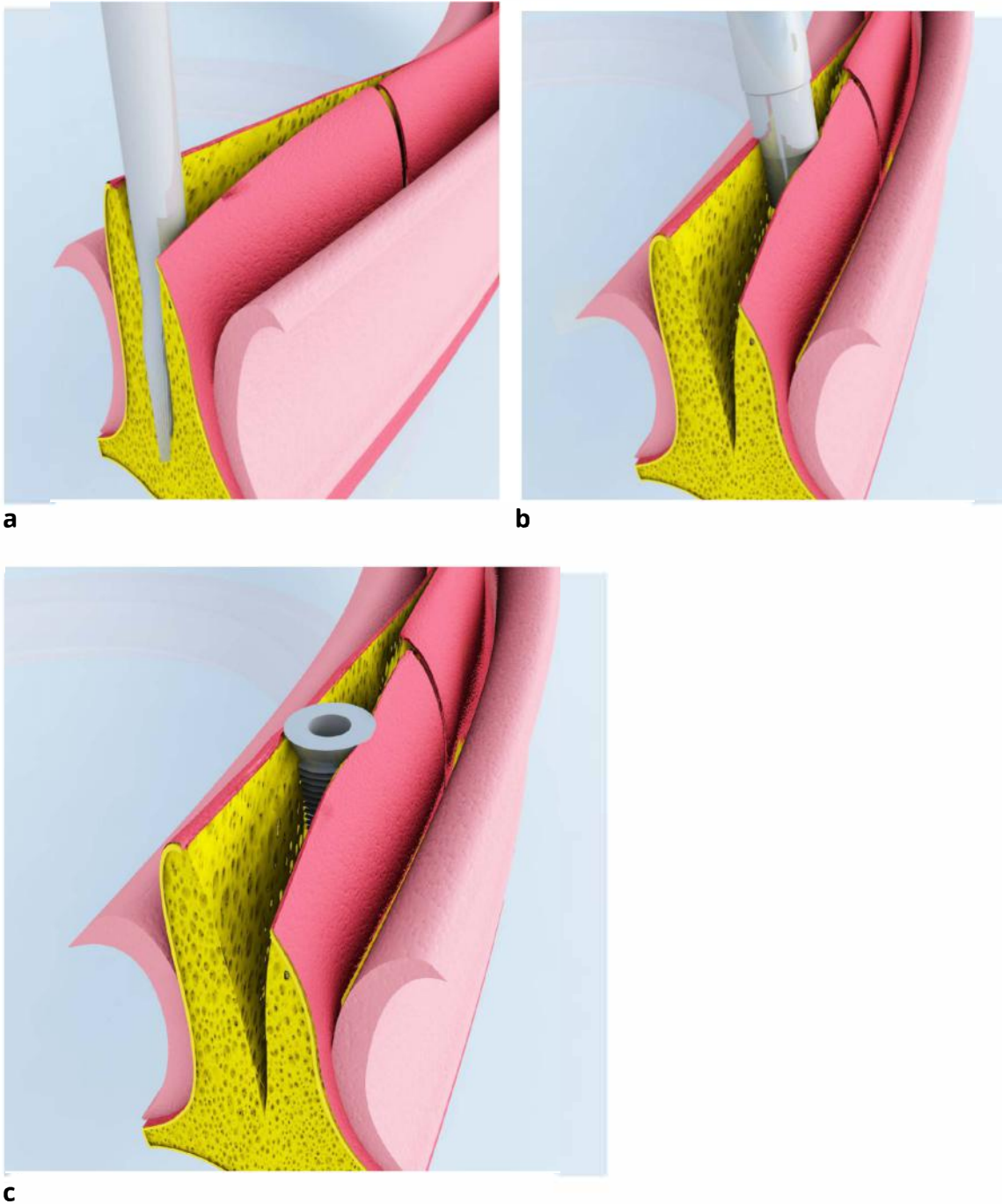


Fig 2 a-c. Schematic view of crestal incision into the bone to perform an intraosseous groove with a blade, sequentially osteotomes till to implant placement.

C. Subsequently a sequence of bone expanders are attached to the handpiece of Magnetic Mallet to perform implant site by expanding the bone tissue both laterally against the preexisting lateral walls and apically, moving up and compressing.

Magnetic Mallet is set to apply different forces to different strength, depending on bone elasticity.

Standard Handpieces:

FORCE NUMBER 2	420 daN
FORCE NUMBER 3	480 daN
FORCE NUMBER 4	540 daN

Plus Handpieces:

FORCE NUMBER 1	370 daN
FORCE NUMBER 2	475 daN
FORCE NUMBER 3	560 daN

In this way, the buccal plate is slowly dislocated in a facial direction. Care must be taken to maintain a zone of spongiosa beneath the cortical plate with a minimum thickness of 1.5 mm. The osteotomy is gradually expanded in 0.5-mm increments using osteotomes inserted to the working depth. The final diameter of the osteotomy is 1.2 mm less than the implant diameter, depending on local bone density. Implants are then placed within the confines of the newly created space.

MAXILLARY BONE EXPANSION

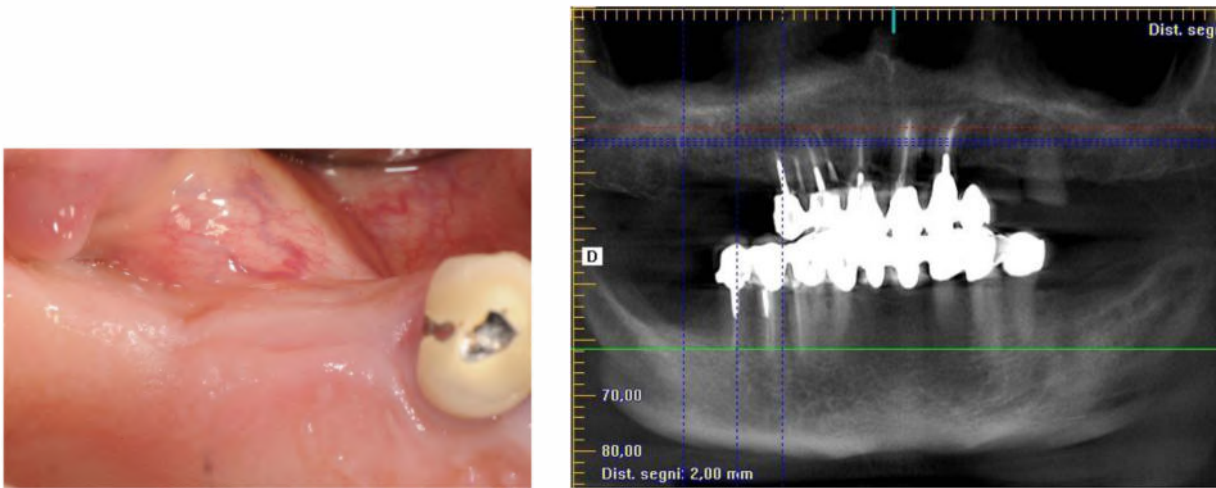


Fig 3,4 Clinical and radiographic aspect of edentulous ridge before treatment

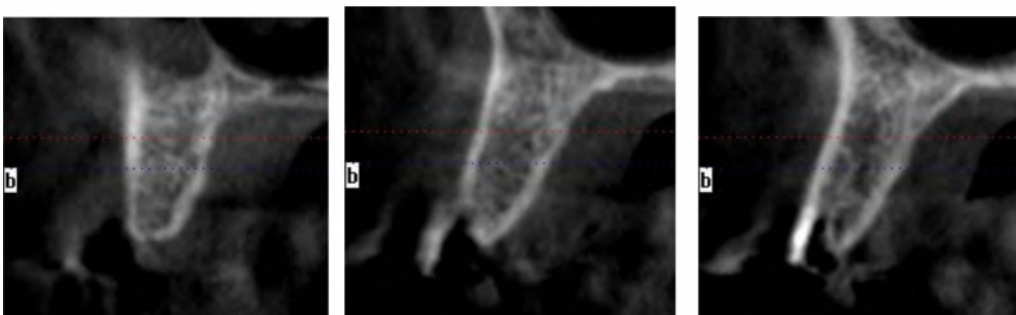


Fig 5a,b,c Cone beam sections of alveolar ridge


Bone incision is performed by blade directly attached and pushed by Magnetic Mallet.

Magnetic Mallet is set to apply **force number 3** (480 daN) for standard handpiece and

force number 2 for plus handpiece (475 daN).

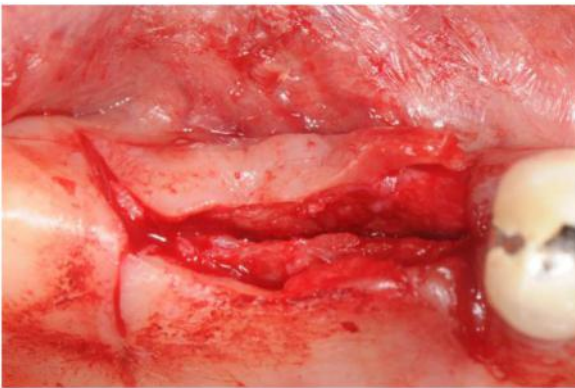

Fig 6. Partial- thickness buccal and lingual flaps are raised, followed by two vertical incisions, horizontal and vertical transperiosteal incisions are made in the bone, the buccal plate is dislocated in vestibular direction



EXP 3 FA

Fig 7 the blade used for bone incisions

Bone expansion is performed by a sequence of bone expanders attached to the handpiece of Magnetic mallet to perform implant site.

Magnetic Mallet is set to apply different forces: force 2 (420 daN) or force 3 (480 daN) for standard handpiece, while force 1 (370 daN) or force 2 (475 daN) for plus handpiece.





Fig 8. Sequence of bone expanders attached to the handpiece of electrical mallet to perform implant site.

The implant are pushed in site by the insert EX F

FORCE NUMBER 3	480 daN	standard handpiece
FORCE NUMBER 2	475 daN	plus handpiece



INS-EX F

Fig 9. Insert for implant placement.

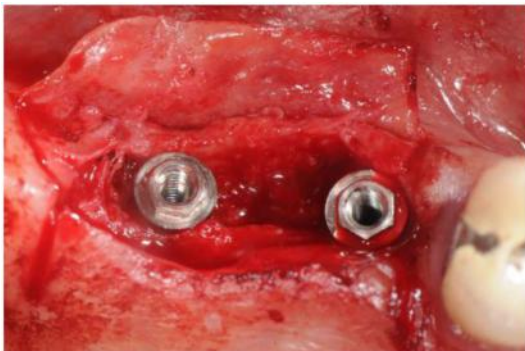

Fig 10. implants are placed within the new created bone space.

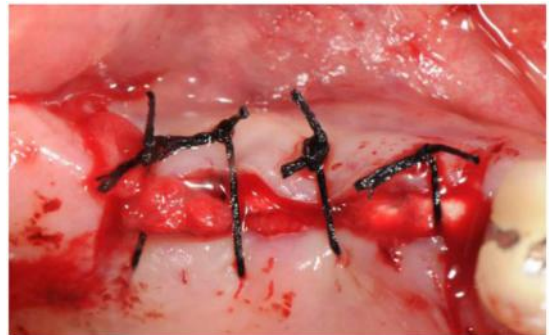

Fig 11. sutures in position.

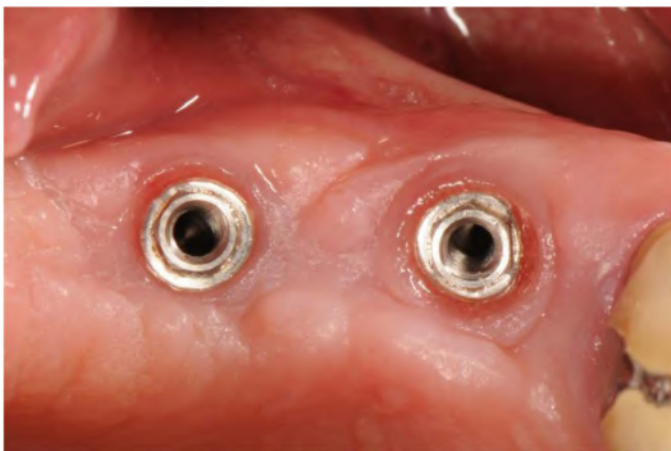

Fig 12. Clinical aspect after four months. It is possible to observe bone volume gain and keratinized gingival thickness.

The buccal flap is apically repositioned and stabilized with sutures tied to the margin of the palatal flap and anchored buccally with a loose loop to the periosteum at the level of the alveolar mucosa. A small piece of collagen, which is inserted below the borders of the soft keratinized mucosa that lines the extraction socket, is used to cover the surgical field. The collagen stops the bleeding and ensures the stability of the blood clot. Fig 11,12


MANDIBULAR

In edentulous mandibular ridge horizontal expansion technique is the same to maxillary bone, Magnetic Mallet is set to apply at greater forces for different strength of mandibular bone.

Bone incision is performed by blade directly attached and pushed by Magnetic mallet.

Magnet Mallet is set to apply **force number 4** (540 daN) for standard handpiece and **force number 3** (560 daN) for plus handpiece.

This blade penetrates down to 7-11 mm into the alveolar ridge. Fig 29-32.



EXP 3 FA



Fig 29 Blade used for bone incision of curved osteotome are used

Fig 30. For molar region these types

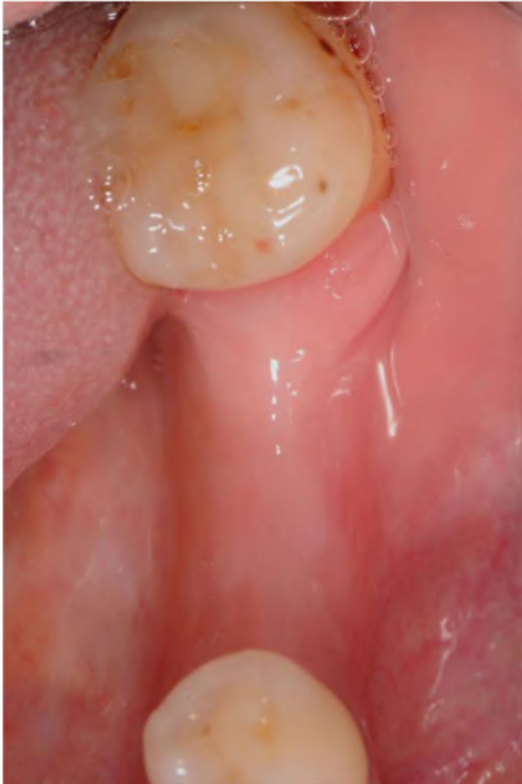

Fig 31 edentulous ridge incisions

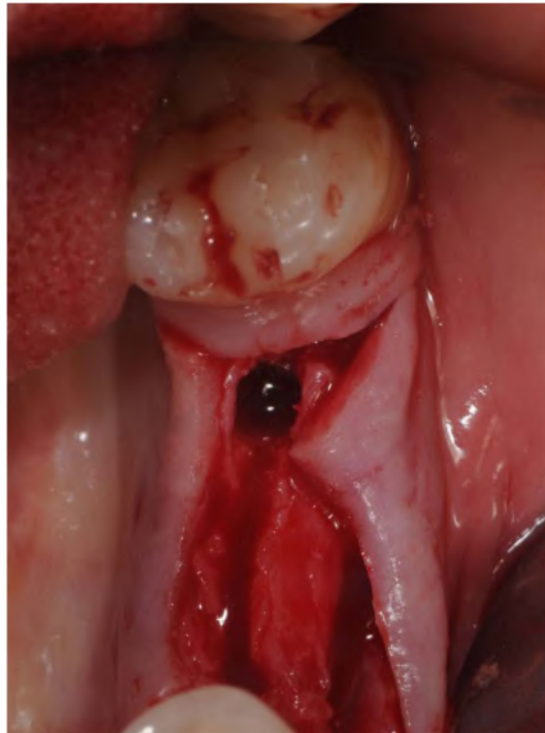


Fig 32. horizontal and vertical transperiosteal

Bone expansion is performed by a sequence of bone expanders attached to the handpiece of Magnetic mallet to perform implant site. Fig 32,33

Magnet Mallet is set to apply different forces: **force number 3** (480 daN) or **force number 4** (540 daN) for standard handpiece, while **force number 2** (475 daN) or **force number 3** (560 daN) for plus handpiece.

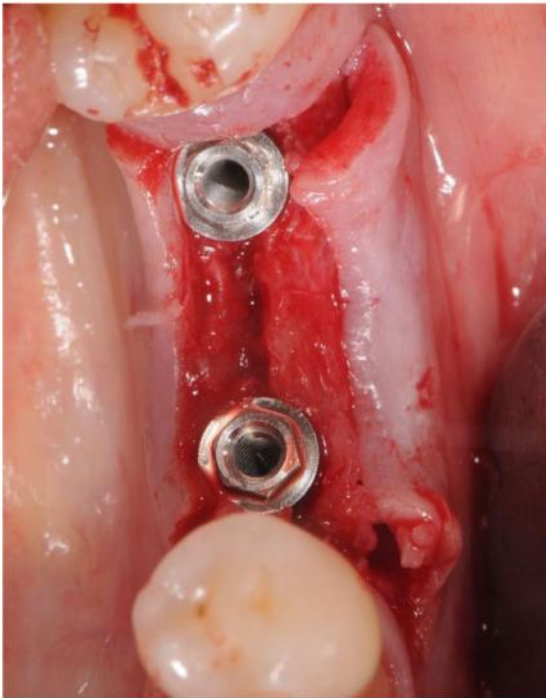


Fig 33. implants are placed within the newly created bone space

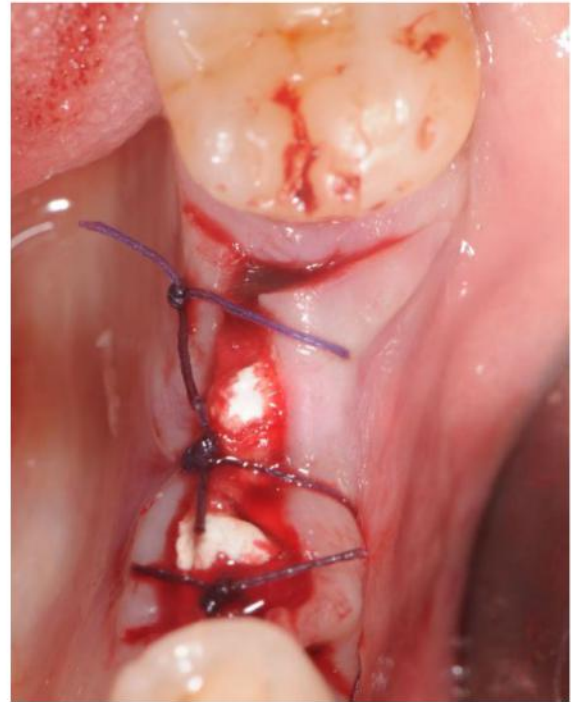

Fig 34. sutures in position

The buccal flap is apically repositioned and stabilized with sutures tied to the margin of the palatal flap and anchored buccally with a loose loop to the periosteum at the level of the alveolar mucosa. A small piece of collagen, which is inserted below the borders of the soft keratinized mucosa that lines the extraction socket, is used to cover the surgical field. The collagen stops the bleeding and ensures the stability of the blood clot.

After 3 months of implant insertion, temporary prostheses are then fitted and worn for 2-3 months before the final reconstruction.

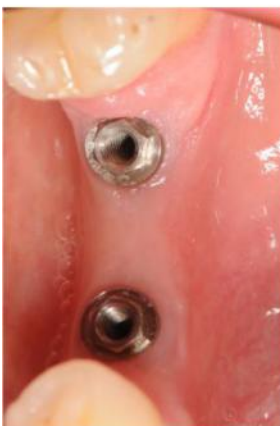

Fig 35 clinical aspect 6 months later