



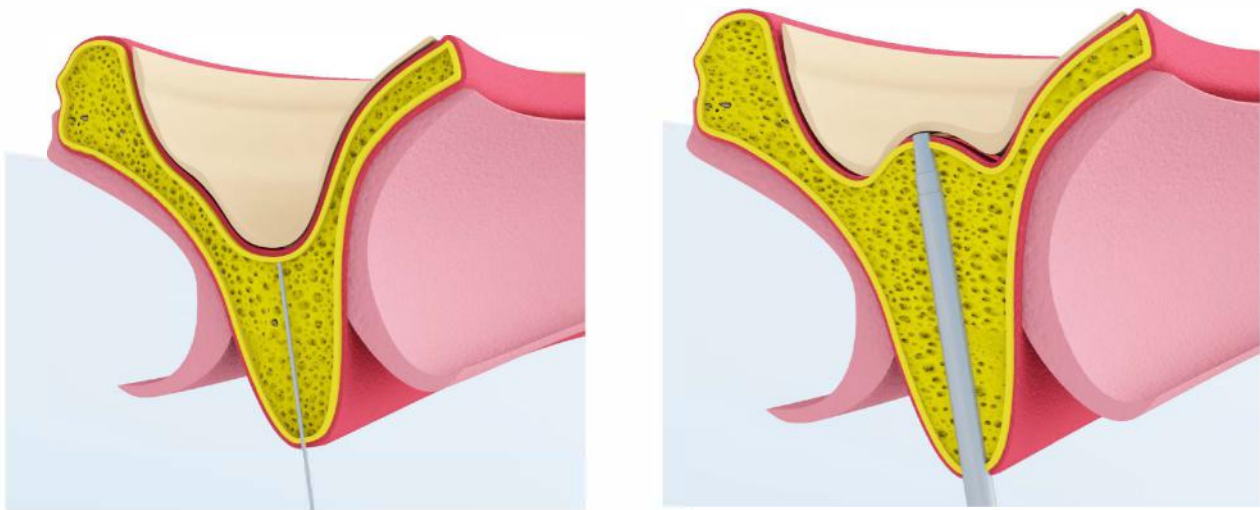
## SINUS LIFT

## Surgical Protocol

According to the prosthetic treatment planning, the location for implant placement is established, and the residual bone height at such locations is first measured on periapical radiographs as the distance from the bone crest to the sinus floor.

**A** The bone crest that needs implant is exposed with a modified partial thickness flap<sup>4</sup> with the tip of the No. 64 Beaver blade. The edentulous bone crest is covered by the preserved suprabony connective tissue and the underlying periosteum. The proposed implant site is first clearly marked with a 2.0-mm round drill.

**B** Direct initial preparation is recommended using a D 160 cylindric osteotome without any initial mechanical drilling to a depth of 0.5 to 1.5 mm from the sinus floor (ie, the working depth) as measured from the preoperative radiographs.



**Fig 4,5** Schematic view of implant site preparation with osteotomes.

Magnetic Mallet is set to apply different forces of different strength, depending on local bone density: **force 2** (420 daN) or **force 3** (480 daN) for standard handpiece, while **force 1** (370 daN) or **force 2** (475 daN) for plus handpiece.

Such sequence of engaged surface progressively act upon and force internal wall of initial hole radially outward with respect to central axis to create high density bone tissue along substantial portion of length of bore wall.



**Fig 6.** Different types of osteotomes are used.

The implant site is created expanding the bone tissue both laterally against the preexisting lateral walls and apically moving up and compressing with hand mallet a progressive series of bone expanders<sup>9</sup>.

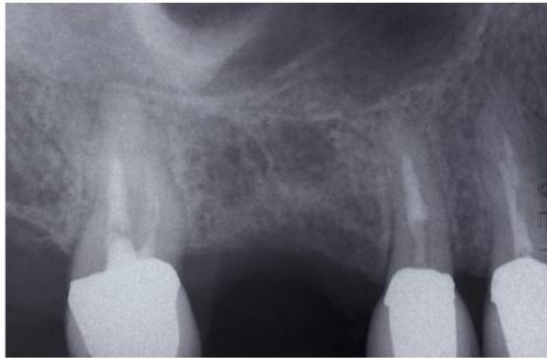
The osteotomy is gradually expanded in 0.5-mm increments using osteotomes D 230, D360 inserted to the working depth. The final diameter of the osteotomy is 0.5 to 1.2 mm less than the anticipated implant diameter, depending upon local bone density. Sinus elevation was delayed until the final apical diameter of the osteotomy (D 360) had been achieved at the desired working depth.

The implant are pushed in site by this insert with a force 3 for standard handpiece and 2 for plus handpiece.



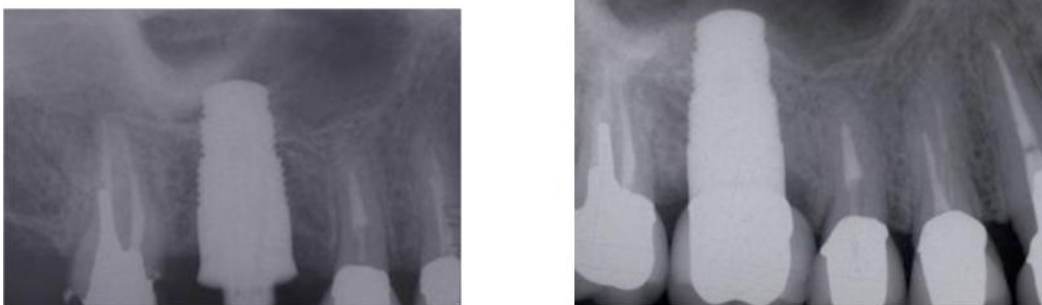**Fig 7** insert for implant placement

Vertical expansion of bone crest is a surgical technique for transcrestal maxillary sinus floor elevation.



**Fig 1.** The distance between the ridge crest and the floor of the sinus

This particular type of bone is usually found below the sinus floor and, through this technique, is displaced vertically in order to create a new implant alveolar portion. In the final configuration of the surgically created alveolus, the coronal portion of the crest must give primary implant stability.



**Fig 2,3.** Periapical radiograph performed immediately and 2 year later; the modified profile or the cortical bone lining the floor of the maxillary sinus can be identified above the implant.